



Use of autogenous tooth bone graft with dental implants

Amirhosein Pakravan¹, Maedeh Yousefnezhad², Amin Heydarian², Tahmineh Bamdadian^{3*}

1. Department of oral and Maxillofacial Surgery, Faculty of Dentistry, Mazandaran University of Medical Sciences, Sari, Iran.

2. Student of Dentistry, Faculty of Dentistry, Student Research Committee, Mazandaran University of Medical Sciences, Sari, Iran.

3. Department of Prosthodontics, Faculty of Dentistry, Mazandaran University of Medical Sciences, Sari, Iran.

ARTICLE INFO

Article Type:
Original Article

Received: 11 May. 2018

Revised: 8 Jun. 2018

Accepted: 25 Aug. 2018

*Corresponding author:

Tahmineh Bamdadian

Department of Prosthodontics, Faculty of Dentistry,
Mazandaran University of Medical Sciences, Sari,
Iran.

Tel: +98-21-33244894

Fax: +98-21-33352725

Email: tbamdadian@Yahoo.com

ABSTRACT

Bone grafting is an appropriate solution for treatment of some cases of bone defect. Till now, different method and biomaterial has been described for bone grafting. According to structural similarities between bone tissue and tooth structure and some successful studies on application of autogenous bone graft materials, we decided to use this biomaterial to treat a bone defect resulting from tooth extraction. In this case, a healthy 36-year-old man visited us for extraction of the left mandibular first molar. In order to preserve the tooth socket, we used the patient's own extracted teeth instead of using routine bone graft materials. The tooth powder processed by the device called the BONMAKER and placed in the socket. After 4 mouths, the radiographic evaluation showed a good bone density. Fixture placement and prosthetic restoration were done and the patient's 5-year follow-up showed good aesthetic, excellent osseointegration and little to no bone resorption, indicating the reliability of this autogenous graft material.

Keywords: Bone graft, Socket preservation, Autograft, Tooth, Implant.

Introduction

Healing of traumatic, infections and neoplastic bone defect are some of the most challenging areas in maxillofacial surgery [1]. About 2.2 million orthopedic bone grafts are performed worldwide every year [2]. Different methods and materials are used in bone graft surgery. Ideal material for bone replacement must have the following four characteristics:

1. Osseointegration: the ability to chemically bond to osseous tissue without an intermediate fibrous tissue layer.
2. Osteoconduction: the ability to conduct and support bone growth by penetrating of capillaries and bone-producing cells into the graft material. A surface with osteoconductive properties let osseous tissue to grow on the

surface or inside its pores.

3. Osteoinduction: inducing multivalent stem cell from adjacent tissues to differentiate into osteoblasts for bone formation. Several articles have been published on heterotropic bone formation in various host locations (such as the anterior chamber of eye or muscle gaps). The best way to show if a material has an osteoinductive capability is to create a specific space within soft tissue like the muscle (where new bone formation usually doesn't occur in normal condition) and place that material there and study new bone formation induced by that material.

4- Osteogenesis: the capability of graft material to form new bone tissue. New bone formation requires the presence of osteoblasts in connective tissues [3-9].

Success in dental implants depends on enough amount of bone in the placing site. Before placing implants, evaluating the existence of sufficient amount of bone in horizontal and vertical aspects is essential; especially in the anterior region of maxilla where aesthetic plays a remarkable role [10]. Several methods have been described on bone reconstruction such as bone blocks or guided bone regeneration (GBR), which are especially used for horizontal bone reconstruction [11]. Vertically reconstruction of alveolar ridge is more challenging and it is more likely to develop complications such as dehiscence, soft tissue contraction and the emergence of hard tissue in the oral cavity [12,13]. To name some, vertical GBR, onlay grafting, inlay grafting, and distraction osteogenesis are widely in use [13-14].

Bone grafting material has been used to maintain space, stabilizing blood clot and forming a scaffold to temporarily trap cells in the site [15]. Bone grafting materials include autografts, allografts, xenografts, and alloplasts which each have their advantages and disadvantages. Teeth are known as a combination of organic and inorganic elements, including large amounts of calcium phosphate minerals, collagen, and other organic elements. Minerals of teeth contain calcium phosphate in 5 different phases (hydroxyapatite, tricalcium phosphate, octo-calcium phosphate, irregular calcium phosphate (TCP) and brachythetic forms). These 5 phases interacting with each other in calcium phosphate crystals [16]. This shows that good bone reconstruction can be achieved when calcium phosphate is placed in a living environment. Apatite crystals form bone tissue and contain ceramics or macromolecules in Nanoscale [17].

The chemical composition of bones and teeth are very similar to each other. 96% of enamel is formed by inorganic components while the organic components and water form the other 4%. The organic to inorganic ratio in dentin is 35:65%, while the cementum has the ratio of 55:45% or 50:50% [18]. Finally, the alveolar bone consists of 65% inorganic and 35% organic particles. Dentin and cementum are composed of a number of components associated with bone growth that include collagen type 1 and bone formation protein (BMP) [18,19]. Type 1 collagen forms about 90% of them and the rest include proteins of non-collagen-

ic proteins such as phosphorylins, sialoproteins, glycoproteins, proteoglycans, bone-forming proteins and biopolymers like lipids, citrates, lactate and etc. They can play the role of promoting bone resorption and bone formation. So teeth originated bone grafts can be useful for clinical use [18-20]. According to structural similarities between bone tissue and tooth structure and some successful studies on the application of autogenous bone graft materials, we decided to use this biomaterial to treat a bone defect resulting from a tooth extraction.

In this case, a healthy 36-year-old man visited us for extraction of the left mandibular first molar. The tooth had previously received endodontic therapy. After clinical examination, it was not considered maintainable due to the severity and extension of caries. As a result, the treatment plan for removing the tooth and replacing it with the implant was considered for this patient. For this purpose, atraumatic extraction of the left mandibular first molar was performed under the local anesthesia achieved by Lidocaine with epinephrine (1:80000) using inferior alveolar nerve block technique (Fig 1). In order to preserve the tooth socket, we used the patient's own extracted tooth instead of using routine bone graft materials.

The tooth was disinfected for 1 to 3 minutes with oxygenated water and then rinsed with water. All of the foreign materials of the tooth (any material such as endodontic sealer, MTA, guttapercha, fiber post, caries, calculus, soft tissue, as well as anything else except mineral tissue of the tooth) were removed as much as possible by the high-speed handpiece. The tooth was dried by air syringe and got crushed. During the process of crushing, other foreign particles of the tooth were removed, such as gutta-percha or residual pulp tissue, etc. After crushing, the tooth powder was passed through the sieve to control the particle size. Large particles were re-crushed from the sieve. This milling and sifting were carried out several times so that the desired volume of the graft material was obtained (Fig 2). The powder was then put into the machine according to the instructions. The Bon Makersystem was used to provide tooth derived bone graft material (Fig 3). 400 ml sterilized distilled water was poured into a special bottle and connected to the device. Each bone reagent material was poured into a special container in accordance with their color code (Fig 4) and the process of preparing the graft material began. This machine is able to process a maximum of 3 CCs of tooth powder at a time. The graft material should be used immedi-

ately and cannot be stored. As a result, the process of preparation of the graft material should be performed during the treatment session. This process took about 26 minutes. At the end of the process, the autogenous tooth bone graft material was extracted from the device and then placed into the tooth socket (Fig 5). After filling the tooth socket with ATB graft material, a collagen membrane was placed over the socket, got fixed. A good healing of soft tissue was observed in the follow-up session after one week.

After 4 months, radiographic imaging showed desirable density in the area (Fig 6, 7). The Dentegris Implant System (4.5×11 mm) was selected for the patient. (Fig 8) After infiltration injection of local anesthetic (Lidocaine with epinephrine (1:80000)), the fixture was placed with the primary stability of 15 N. After placing the cover screw, the flap was closed using absorbable suture. After three months, it was loaded with a metal-ceramic crown. The patient's 5-year follow-up showed good aesthetic, excellent osseointegration and little to no bone resorption, indicating the reliability of this autogenous graft material (Fig 9).

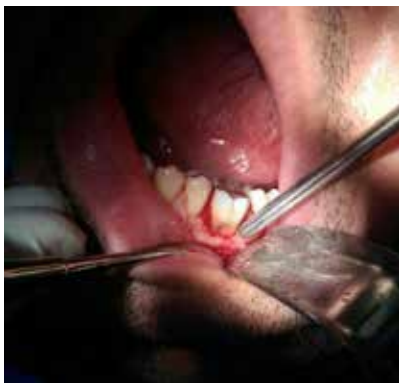

Figure 1. Left first molar mandibular before extraction



Figure 2. Tooth powder after several times of millings and siftings.



Figure 3. The Bon Maker system was used to provide tooth derived bone graft material.



Figure 4. Bone reagent material (color coded).

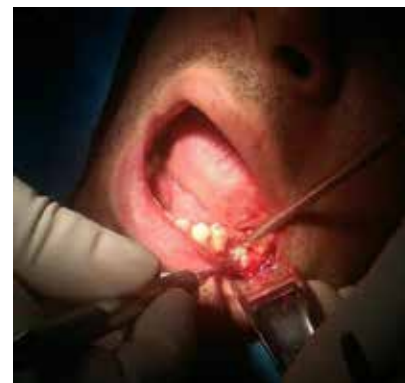

Figure 5. Placing the autogenous graft material.

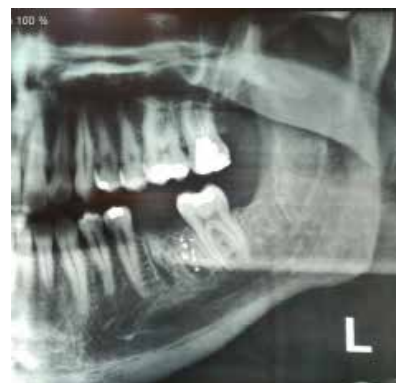

Figure 6. After 4 months, radiographic imaging showed desirable density in the area.

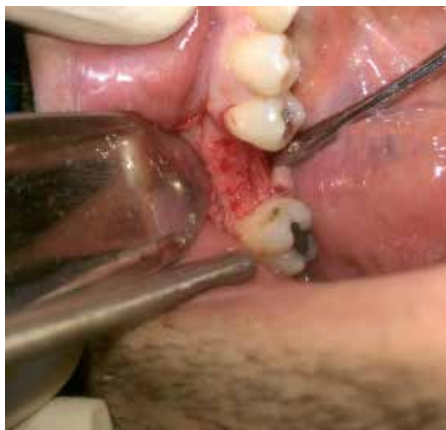

Figure 7. A good bone regeneration was observed after retracting subperiosteal flap.

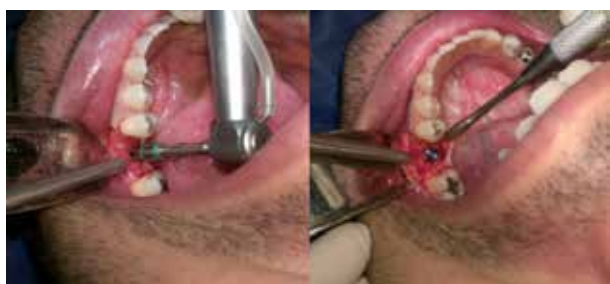

Figure 8. Placing the Dentegris Implant System (4.5 × 11 mm), the fixture was placed with the primary stability of 15 N. After placing the cover screw, the flap was closed using absorbable suture.

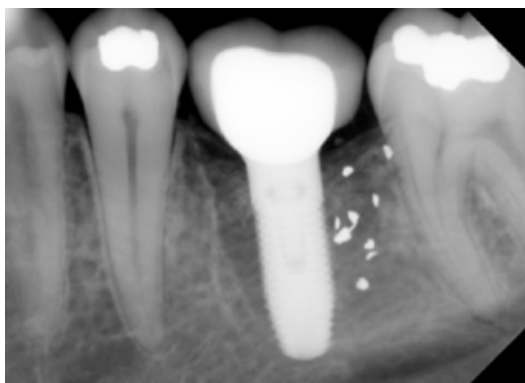


Figure 9. Five-year follow up.

Discussion

Many investment companies and researchers work in the field of osteopromotive materials which support bone repair. Compared to the various materials that have been studied, Autogenous demineralized dentin matrix (ADDM) used in bone defects has shown great results since they contain bone marrow protein and can be re-absorbed [1,21,22] Also, there are several studies indicating that using bone morphogenic protein, osseous or demineralized dentin matrix will contribute

to a better bone repair [23-25]. A graft material must be biocompatible, easy to use and cost-effective [1,22]. Autogenous Tooth Bone (ATB) graft biomaterials were made from the tooth itself so it requires an advanced technology that was demonstrated in this paper. The Autogenous tooth bone graft advantages are as follows:

1. Osteogenesis, osteoinduction, and osteoconduction capability.
2. Being safe and reliable and not having any risk of immune responses.

ATB graft material, by supporting bone remodeling, is helping the bone to resist the mastication forces and has a great role in the long-term success of dental implants. It is combinable and if there is an insufficient amount of ATB graft, ATB can be combined with other graft materials during treatment.

Kim and colleagues presented the production of partially demineralized tooth bone graft material and freezing-drying technologies for the first time in the international arena. They studied the mineral components of the freshly extracted teeth and examined the ATB graft material treated sample and found that the coronal part of the tooth mostly formed by high-crystalline calcium phosphate and the root is mainly composed of low-crystalline calcium phosphate [26,27].

Since the bone tissue is mainly formed by low-crystalline apatite, if dentin and cementum, which make up a large percentage of tooth, are used as bone materials, osteoconduction and a good bone remodeling are expected. They analyzed the harvested mandibular cortical bone from the patients who were treated with following graft materials: coronal ATB graft, root ATB graft, xenograft bone, irradiated mineralized allogeneic cancellous bone and synthetic bone MBCP. They analyzed the samples using x-ray diffraction (XRD) and found that dentin ATB graft and allograft bone have the most similar pattern [28].

Other researchers in their Case Reports have reported good results in sinus bone grafting, ridge augmentation, guided bone regeneration (GBR), socket preservation, and expressed the effectiveness of this substance in the elimination of hard tissue defects [28]. Jeong and colleagues conducted a study on osteogenesis after ATB graft on miniature pigs.

They reported an average of 74.43% bone formation after 4 weeks and introduce it as a good alternative to bone grafting. This significant percentage is also a back-

bone for the application of this technique. The normal clinical and radiological assessments of the patient in this study over the 4 years follow up have confirmed these findings and demonstrated the benefits of ATB graft as a method in the treatment of pre-implantation bone defects [29].

The safety of ATB graft material has been proven to be an effective and useful alternative for autogenous bone grafts. Due to its organic and non-organic molecules, it has also shown excellent osteoinduction and osteoconduction in bone healing. Finally, According to all aforementioned properties of ATB graft and also considering the fact that teeth contain the most similar material to the bone; ATB graft material can be referred to as one of the best forms of graft materials to this moment.

Conclusion

In this case report it was shown that good aesthetic, excellent osseointegration and little to no bone resorption, indicating the reliability of this autogenous graft material.

Conflict of Interest

There is no conflict of interest to declare.

References

- [1] Catanzaro-Guimarães S, Catanzaro BP, Garcia GR, Alle N. Osteogenic potential of autogenic demineralized dentin implanted in bony defects in dogs. *International journal of oral and maxillofacial surgery*. 1986; 15(2):160-9.
- [2] Van Heest A, Swionkowski M. Bone-graft substitutes. *The Lancet*. 353:S28-S9.
- [3] Cypher TJ, Grossman JP. Biological principles of bone graft healing. *The Journal of foot and ankle surgery*. 1996; 35(5):413-7.
- [4] Costantino PD, Friedman CD. Synthetic bone graft substitutes. *Otolaryngologic Clinics of North America*. 1994; 27(5):1037-74.
- [5] Urist MR, Mc LEAN FC. Osteogenetic potency and new-bone formation by induction in transplants to the anterior chamber of the eye. *JBJS*. 1952; 34(2):443-75.
- [6] Levander G. A study of bone regeneration. *Surg Gynecol Obstet*. 1938; 67(6):705-14.
- [7] Huggins C. The formation of bone under the influence of epithelium of the urinary tract. *Archives of Surgery*. 1931; 22(3):377-408.
- [8] Branemark P. Osseointegrated implants in the treatment of the edentulous jaw. Experience from a 10-year period. *Scand J Plast Reconstr Surg*. 1977; 11(16):1-132.
- [9] Albrektsson T, Brånemark P-I, Hansson H-A, Lindström J. Osseointegrated titanium implants: requirements for ensuring a long-lasting, direct bone-to-implant anchorage in man. *Acta Orthopaedica Scandinavica*. 1981; 52(2):155-70.
- [10] Javed F, Ahmed HB, Crespi R, Romanos GE. Role of primary stability for successful osseointegration of dental implants: Factors of influence and evaluation. *Interventional Medicine & Applied Science*. 2013; 5(4):162-7.
- [11] Mc Allister BS, Haghighat K. Bone augmentation techniques. *Journal of periodontology*. 2007; 78(3):377-96.
- [12] Jensen SS, Terheyden H. Bone augmentation procedures in localized defects in the alveolar ridge: clinical results with different bone grafts and bone-substitute materials. *International Journal of Oral & Maxillofacial Implants*. 2009; 24.
- [13] Esposito M, Grusovin MG, Felice P, Karatzopoulos G, Worthington HV, Coulthard P. Interventions for replacing missing teeth: horizontal and vertical bone augmentation techniques for dental implant treatment. *The Cochrane Library*. 2009.
- [14] Rocchietta I, Fontana F, Simion M. Clinical outcomes of vertical bone augmentation to enable dental implant placement: a systematic review. *Journal of clinical periodontology*. 2008; 35(s8):203-15.
- [15] Pellegrini G, Pagni G, Rasperini G. Surgical approaches based on biological objectives: GTR versus GBR techniques. *International journal of dentistry*. 2013; 2013.
- [16] Lee D, Glimcher M. Three-dimensional spatial relationship between the collagen fibrils and the inorganic calcium phosphate crystals of pickerel (*Americanus americanus*) and herring (*Clupea harengus*) bone. *Journal of molecular biology*. 1991; 217(3):487-501.

- [17] Lee S-H. Low Crystalline Hydroxyl Carbonate Apatite. The journal of the Korean dental association. 2006; 44.
- [18] SN. B. Orban's oral histology and embryology. 9 ed. Saint Louis: Mosby Co.; 1980.
- [19] BM. M. Oral biochemistry. Seoul: Daehan Narae Pub Co; 2007.
- [20] Nanci A. Enamel: composition, formation, and structure 2008. 141-90 p.
- [21] Gomes MF, da Silva dos Anjos MJ, de Oliveira Nogueira T, Guimarães SAC. Autogenous demineralized dentin matrix for tissue engineering applications: radiographic and histomorphometric studies. International Journal of Oral & Maxillofacial Implants. 2002; 17(4).
- [22] Gomes MF, Da Silva Dos Anjos MJ, de Oliveira Nogueira T, Guimarães SAC. Histologic evaluation of the osteoinductive property of autogenous demineralized dentin matrix on surgical bone defects in rabbit skulls using human amniotic membrane for guided bone regeneration. International Journal of Oral & Maxillofacial Implants. 2001; 16(4).
- [23] Gao Y, Yang L, Yamaguchi A. Immunohistochemical demonstration of bone morphogenetic protein in odontogenic tumors. Journal of oral pathology & medicine. 1997; 26(6):273-7.
- [24] Raval P, Hsu H, Schneider D, Sarras Jr M, Masuhara K, Bonewald L, et al. Expression of bone morphogenetic proteins by osteoinductive and non-osteoinductive human osteosarcoma cells. Journal of dental research. 1996; 75(7):1518-23.
- [25] Rosen V TR. The Cellular and Molecular Basis of Bone Formation and Repair. Heidelberg: Springer; 1995.
- [26] Kim Y-K, Kim S-G, Oh J-S, Jin S-C, Son J-S, Kim S-Y, et al. Analysis of the inorganic component of autogenous tooth bone graft material. Journal of nanoscience and nanotechnology. 2011;11(8):7442-5.
- [27] Kim Y-K, Kim S-G, Byeon J-H, Lee H-J, Um I-U, Lim S-C, et al. Development of a novel bone grafting material using autogenous teeth. Oral Surgery, Oral Medicine, Oral Pathology, Oral Radiology and Endodontics. 2010; 109(4):496-503.
- [28] Kim Y-K. Clinical application and classification of bone graft material according to component. The journal of the Korean dental association. 2010; 48.
- [29] Jeong H-R, Hwang J-H, Lee J-K. Effectiveness of autogenous tooth bone used as a graft material for regeneration of bone in miniature pig. Journal of the Korean Association of Oral and Maxillofacial Surgeons. 2011; 37(5):375-9.

Please cite this paper as:

Pakravan A, Yousefnezhad M, Heydarian A, Bamdadian T; Use of autogenous tooth bone graft with dental implants. J Craniomax Res 2018; 5(3): 125-130